

**PATIENT**

Bean McCoy

SPECIES

Canine

BREED

Chihuahua Mix

SEX

MN

AGE

13yr

WEIGHT

13lb

INTERPRETED BY

R. McKenzie Daniel,
DVM, DABVP
(Canine and Feline)

**IMAGING
PERFORMED BY**

Brita Kiffney

HOSPITAL NAME

Northshore Veterinary
Hospital

REFERRING VET

Brita Kiffney

**INVOICE
23360**

DATE
12/24/2025

PRESENTING CLINICAL SIGNS

diagnosed with left anal gland adenocarcinoma diagnosed last week ,

Abnormal PE/Chem/CBC/UA Results: normal labs, not hypercalcemic

ULTRASONOGRAPHIC EXAMINATION OF THE ABDOMEN**Urinary System**

The urinary bladder, trigone, cystourethral junction, and visible pelvic urethra to a depth of 2 cm exhibited normal thickness and tone. Anechoic urine was present in the lumen with no evidence of urine/lumen sediment, mineral, or calculi. The ureteral papillae were normal. The ureters were not visible which is normal. No evidence of inflammatory or neoplastic changes was noted.

Normal size and margination were present in the kidneys. A normal 1:3 cortex / medulla ratio was maintained. The medulla and cortices were uniform in texture with some increased echogenicity and mild loss of corticomedullary symmetry and definition expected for the age of the patient. No evidence of pelvic dilation was present. Bilateral areas of mild medullary mineral were present. The left kidney measured 4.0 cm in length. The right kidney measured 4.3 cm in length.

The area of the iliac trifurcation was free of pathology including no evidence of medial iliac or sublumbar lymphadenopathy or masses.

The residual prostate appeared normal and free of pathology measuring 0.84 cm in diameter.

Adrenal Glands

The bilateral adrenal glands were normal in size. Mild parenchyma heterogeneity and mild capsule asymmetry was present without suspicion for overt neoplasia. The left adrenal gland measured 0.51 cm width in the caudal pole. The right adrenal gland measured 0.47 cm width in the caudal pole.

Spleen

The spleen exhibited a primarily finely textured and homogenous parenchyma which was hyperechoic to the liver and renal cortical parenchyma. A solitary, non-capsule deforming hypoechoic cranial splenic nodule was present measuring 0.55 cm in diameter. Mild hypoechoic perihilar splenic parenchyma was present

Liver/Gallbladder

The liver was subjectively normal in size, structure, and contour. The liver parenchyma was uniform and hypoechoic to the spleen with a mild coarse echotexture. Normal vascular volume. The hepatic and portal vasculature were normal in appearance without signs of congestion. The gallbladder was non-distended in size with thin walls and primarily anechoic luminal content. The cystic and common bile ducts were normal.

Gastrointestinal

The stomach presented intact wall layering with a normal wall layer ratio. The lumen of the stomach contained mild non-shadowing ingesta sonographically suggestive of food echogenicity with no signs of ileus, obstruction or foreign material.



PATIENT

Bean McCoy

The small intestine presented intact wall layering with 1:3 muscularis/mucosa ratio. The lumen of the small intestine was empty with no signs of mechanical/metabolic ileus, obstruction or foreign material.

Normal visible colon wall layers were present with apparent formed feces in lumen.

SPECIES

Canine

Pancreas

The area of the pancreas was sonographically normal.

Free Abdomen

BREED

Chihuahua Mix

No omental masses, overt lymphadenopathy or peritoneal effusion was present.

ULTRASONOGRAPHIC FINDINGS

SEX

MN

Primary

- Non-disruptive splenic nodule
- Age-related renal/ adrenal changes.

AGE

13yr

INTERPRETATION OF THE FINDINGS & FURTHER RECOMMENDATIONS

No evidence of caudal abdomen, retroperitoneal or lymphatic metastatic criteria. The splenic nodule is nonspecific and may indicate lymphoid hyperplasia, hematopoiesis, granuloma or possible emerging primary or metastatic splenic tumor. Assuming normal clotting status, using 25ga needle, a splenic nodule FNA cytology is warranted for further clarification. Sonographic monitoring of the splenic nodule for evidence of progression would be reasonable.

WEIGHT

13lb

INTERPRETED BY

R. McKenzie Daniel,
DVM, DABVP
(Canine and Feline)

IMAGING PERFORMED BY

Brita Kiffney

HOSPITAL NAME

Northshore Veterinary
Hospital

REFERRING VET

Brita Kiffney

INVOICE

23360

DATE

12/24/2025



PATIENT

Bean McCoy

SPECIES

Canine

BREED

Chihuahua Mix

SEX

MN

AGE

13yr

WEIGHT

13lb

INTERPRETED BY

R. McKenzie Daniel,
DVM, DABVP
(Canine and Feline)

IMAGING PERFORMED BY

Brita Kiffney

HOSPITAL NAME

Northshore Veterinary
Hospital

REFERRING VET

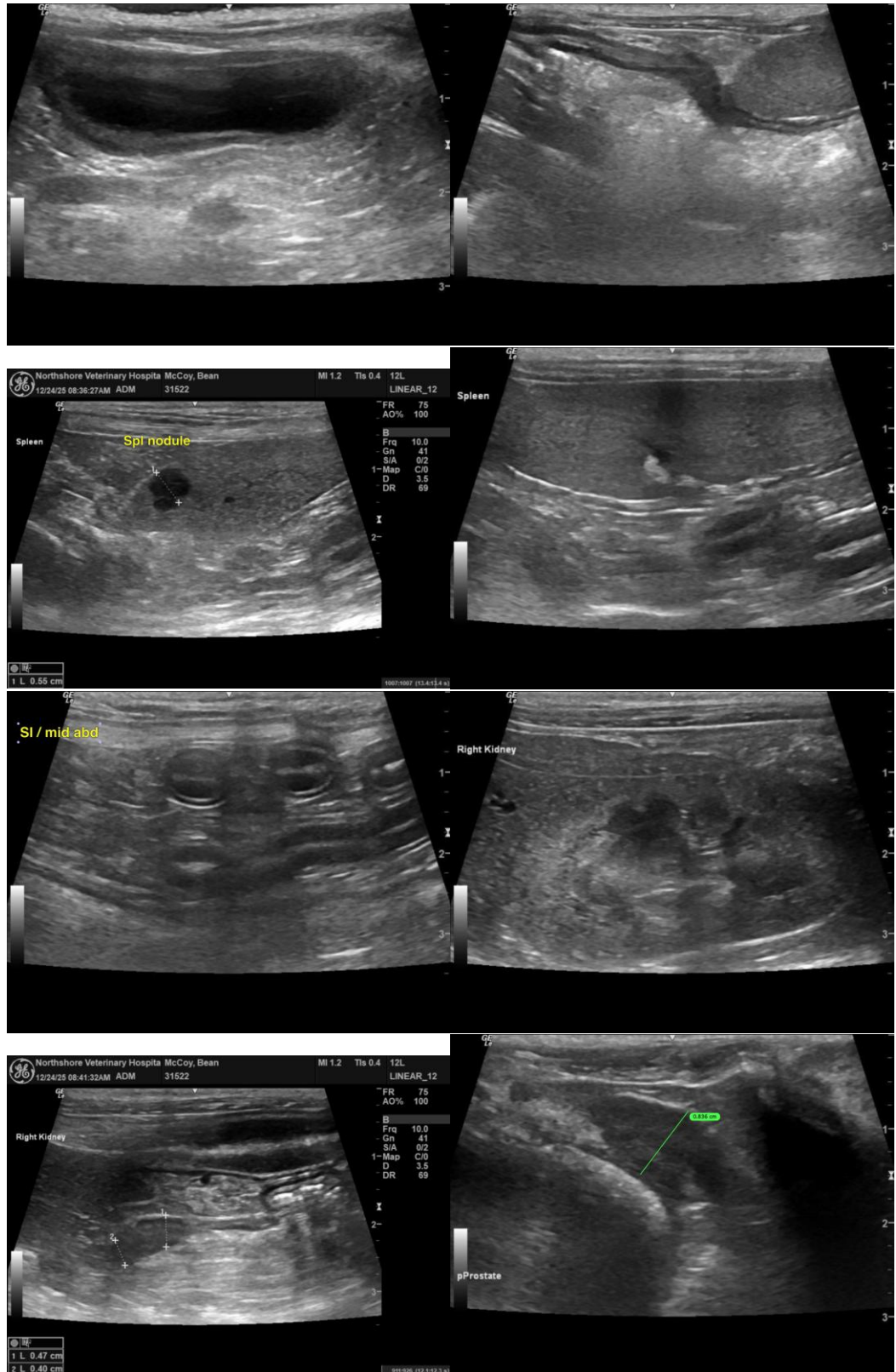
Brita Kiffney

INVOICE

23360

DATE

12/24/2025





PATIENT

Bean McCoy

SPECIES

Canine

BREED

Chihuahua Mix

SEX

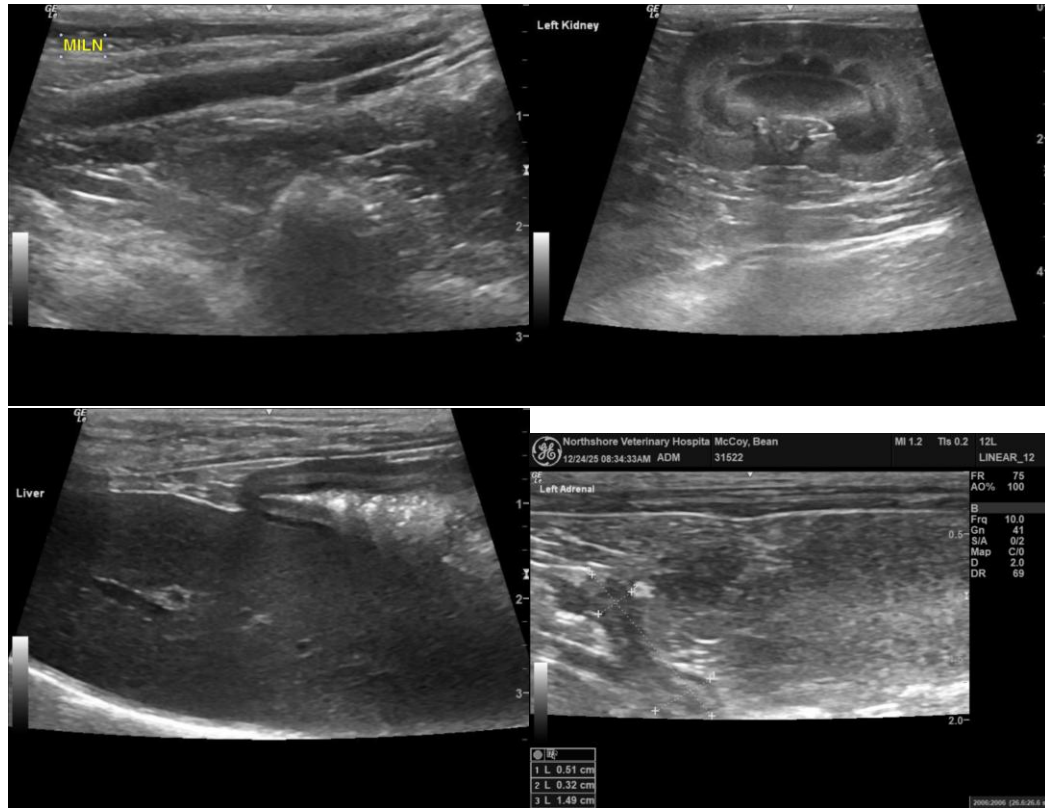
MN

AGE

13yr

WEIGHT

13lb



INTERPRETED BY

R. McKenzie Daniel,
DVM, DABVP
(Canine and Feline)

IMAGING PERFORMED BY

Brita Kiffney

HOSPITAL NAME

Northshore Veterinary Hospital

REFERRING VET

Brita Kiffney

INVOICE

23360

DATE

12/24/2025

The information and recommendations provided are based on the images presented by the referring veterinarian/sonographer. No evaluation can be communicated regarding pathology that was not visible in the image/video clips provided.

Thank you for this referral. If the clinical or image interpretation does not parallel your findings or if I can be of any further assistance, please contact me.

R. McKenzie Daniel, DVM, DABVP (Canine/Feline Practice)
info@sonopath.com